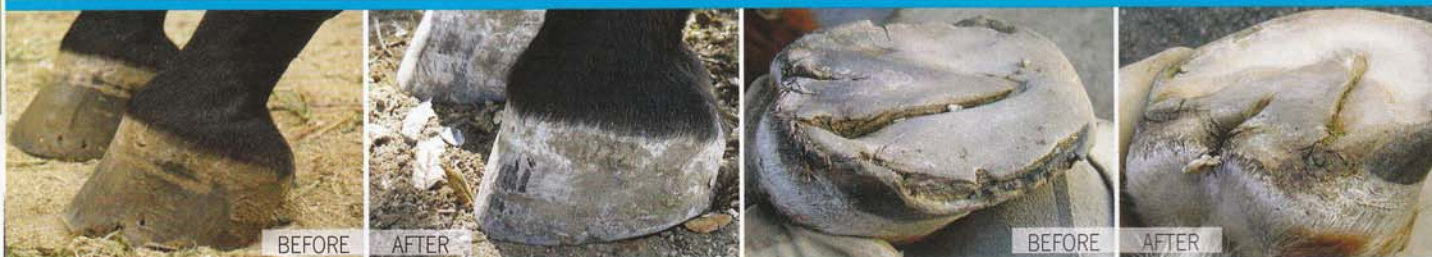

HOOF ANATOMY 101



Confused by farrier jargon, and unsure how much you need to understand about your horse's feet? In this informative Q&A, a professional natural hoof care practitioner walks you through basic hoof anatomy.

WITH JAIME JACKSON



Have you ever read an article on hoofcare or trimming and wondered, “Where is that part of the hoof?” or “What does that structure do?” Chances are, your answer is “yes”. We asked natural hoof care practitioner Jaime Jackson to take us back to basics, and break things down for riders so they might develop a better understanding of their horses’ hooves.

EW *Is it important for riders to understand basic hoof anatomy? Why or why not?*

JJ Familiarizing yourself with basic hoof structures would be responsible in my opinion. It’s of vital importance to understand what a healthy hoof looks like and to recognize the meaning behind telltale unhealthy symptoms showing up in the hoof. Lamellar stress rings, club foot, visible red in the “white” line, and separation of the white line from the hoof wall are most often indicators of horse management issues, including diet, movement

and improper riding, trimming and shoeing.

EW *Is there such a thing as “too much” knowledge when it comes to your horse’s feet?*

JJ I think there are reasonable “limits” to what horse owners (as well as professional hoof trimmers and even veterinarians) should be expected to know. Because of the anatomical complexity of the hoof, and because defining research that explains natural hoof structure and function is yet to be conducted by qualified equine veterinary scientists, it is problematic and probably self-defeating for riders to wade through a myriad of published technical papers, anatomy/physiology texts, and, of course, the burgeoning “opinions” spread across the internet.

You can find an abundance of excellent information on hoof health, anatomy, and responsible care; and as an

advocate and educator for better care and useful information, I do direct horse owners to recommended resources. For example, in my book *Horse Owners Guide To Natural Hoof Care*, I've sketched and identified the structure of the hoof as well as my observations and speculations concerning the hoof during support and flight. Too much knowledge is less of a concern than simply not understanding the hooves. They are to the horse what canaries are to coal miners!

EW *What are the basic parts of the hoof that people should know/understand, and what should they be aware of in regards to each (form, function, etc)?*

JJ Basic information would include identification of the bones below the fetlock joint, terminating in the "coffin bone" (P3); the major extensor and flexor tendons responsible for rotating the hoof forwards and backwards during flight and support; and, perhaps surprisingly, the five dermal "coria" responsible for hoof growth and connection to the horse (see sidebar). The latter are interconnected and form what I call a "supercorium".

Collectively, these are extremely important because they not only produce the hoof – and everything inside it – but also direct its growth patterns and supply its nutritional needs. The supercorium is also highly susceptible to disease and inflammation, including life-threatening laminitis (separation of the hoof from the horse), and is sensitive to what we put into the horse (feeds, supplements, drugs, vaccinations, etc.). So, it's important that we understand the relationship between this structure and our care practices.

Awareness of the "white line" is also crucial. This is the narrow "leaf-like" structure that divides the hoof wall (including the bars) from the sole. Never "white" (a misnomer), the white line is a positive indicator of stress (including laminitis) when the leaves either widen and/or turn red.

EW *Does every horse's foot look the same? How do you know if your horse is "normal"?*

JJ While the hooves of no two horses are identical, there are characteristics that all healthy, naturally shaped hooves should share:

- Hoof walls should be straight, neither concave (growing downward at different angles from the coronary band to the ground – called DTA's or "diverging toe angles" by natural hoof care practitioners) nor convex ("bull nosed", the hoof growing at a steeper angle near the ground than just below the coronary band).
- The outer wall should be smooth and free of "stress rings", either bulging or furrowed growth rings rippling below and parallel to the coronary band – warnings from nature of possible acute laminitic episodes.
- Front hooves should be slightly larger and more rounded at the toe than corresponding hinds.

My horse, my forever friend.



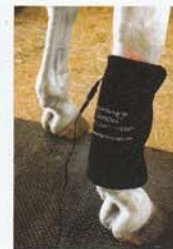Inspire me Equine™

Marketing inspiration to horse enthusiasts through our beautiful photographs with words that express how you feel!

For our online catalog of current greeting card products. Visit us at www.inspiremeequine.com

According to 'Gospel'...

Equine Light Therapy



2 sizes do it all!

Easy to use and AFFORDABLE!

Small Light Pad

\$299

Large Light Pad

\$499

Gentle and Effective!



Illuminating the future of equine care

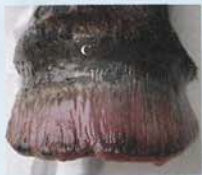**JOIN US AT THE OHIO EQUINE AFFAIRE
APRIL 8-11, BRICKER BUILDING, BOOTH #615**

**615.293.3025
EquineLightTherapy.com**

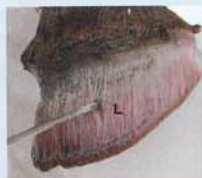- Left and right hooves should be symmetrical relative to size, shape, and proportion.
- Soles should be concaved rather than “flat” or “bulging” (symptoms of chronic laminitis or compaction).
- With few exceptions, all toe lengths should measure less than 3¾”.

- Hoof angles should measure above 45°, and less than 65°; hinds will usually measure higher than corresponding fronts.
- Frogs will be dry and tough during summer months, moist and spongy during rainy periods. Moist, smelly, spongy or “craggy” frogs during the arid times of the year (although any time of the year) are probably suffering from “thrush”, a variation of Superficialis.
- Hoof walls should be approximately the same thickness all around (i.e., from toe to heel), with a ridge of horn – called the “water line” – protruding just below (i.e., towards the ground) the white line.
- The hoof wall should be well-rounded (beveled) outwards from the outer edge of the water line.

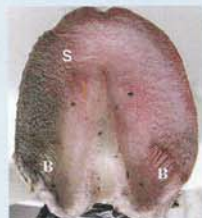
THE FIVE DERMAL “CORIA”



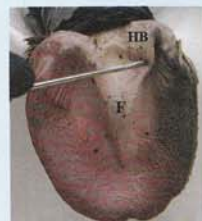1. CORONARY CORIUM
responsible for producing the hoof wall



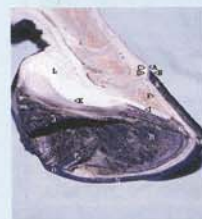2. LAMINAR CORIUM
responsible for producing the epidermal leaves that connect the hoof wall to the horse



3. SOLAR CORIUM
responsible for producing the sole




4. FROG/BULB CORIUM
responsible for producing the frog and heel bulbs



5. PERIOPLIC CORIUM
responsible for producing the flexible, thin layer of epidermal horn covering the coronary band (the outer edge of the coronary corium above the hoof wall) and connecting the hoof to the hairy skin above

EW *What obvious changes in hoof anatomy/structure are cause for alarm?*

JJ You should be on the alert for variations in the angle of wall growth (either convex or concave), the presence of flare or stress rings in the outer wall, a stretched or red “white line”, a flat or bulging sole, a shriveled, moist, smelly and/or disfigured frog. Other concerns are sole/frog/bulb abscesses, deep/bleeding wall splits, and hooves unable to go barefoot due to hypersensitivity. Any of these symptoms are probable indicators of hoof and other horse care management problems.

Having a good, basic understanding of hoof form and function will be beneficial to your trimmer and your horse’s overall health and well being! 

JAIME JACKSON IS A 35-YEAR VETERAN HOOF CARE PROFESSIONAL, LECTURER, AUTHOR, RESEARCHER AND NOTED EXPERT ON WILD AND DOMESTIC HORSE HOOVES. IN THE EARLY 2000S, JAIME CREATED THE AMERICAN ASSOCIATION OF NATURAL HOOF CARE PRACTITIONERS, NOW CALLED THE ASSOCIATION FOR THE ADVANCEMENT OF NATURAL HORSE CARE PRACTICES (AANHCP.NET). HE HAS WRITTEN TWO BOOKS: *THE NATURAL HORSE: LESSONS FROM THE WILD*, AND MOST RECENTLY, *Paddock Paradise: A Guide to Natural Boarding*. JAIME RESIDES IN CENTRAL CALIFORNIA AND CONTINUES TO MAINTAIN A TRIMMING AND REHABILITATION CLIENT BASE.